

CASE REPORT

Cecal diverticulitis with atypical presentation in a 57-year-old man: a case report

Maryam Hafazalla^{1*}, Thomas Coryndon¹, Heba Doudi²

ABSTRACT

Background: Right-sided diverticulitis, particularly cecal diverticulitis, is a rare condition that can mimic other causes of an acute abdomen and pose a diagnostic challenge.

Case Presentation: A 57-year-old man presented with acute tearing epigastric pain followed by lower abdominal pain. Examination revealed bilateral iliac fossa tenderness with guarding in the right iliac fossa and positive psoas and obturator signs. Laboratory testing showed elevated C-reactive protein (70 mg/l) with otherwise unremarkable results. Because of the initial tearing epigastric pain, there was concern for serious conditions, including acute coronary syndrome, pancreatitis, and aortic pathology; therefore, cardiac enzymes, Electrocardiogram, serum lipase, and contrast-enhanced computed tomography (CT) were obtained, which excluded these diagnoses. Abdominal ultrasound demonstrated focal bowel wall thickening in the right lumbar region. Contrast-enhanced CT identified a cecal diverticulum with surrounding pericolic fat stranding and localized inflammatory changes without abscess or perforation, consistent with Hinchey stage Ia cecal diverticulitis. The patient was managed conservatively with intravenous ceftriaxone and metronidazole, providing broad-spectrum gram-negative and anaerobic coverage, and showed rapid clinical improvement.

Conclusion: Cecal diverticulitis might present atypically and mimic other causes of acute abdomen. Early cross-sectional imaging is crucial for accurate diagnosis, and conservative antibiotic therapy is effective in uncomplicated cases.

Keywords: Cecal diverticulitis, right-sided diverticulitis, acute abdomen, conservative management, case report.

Introduction

Diverticular disease predominantly affects the left colon, whereas right-sided diverticulitis is relatively uncommon. Cecal diverticulitis presents a diagnostic challenge due to its overlap with other causes of acute abdominal pain, particularly acute appendicitis [1-3].

Although right-sided diverticulitis is more commonly reported in Asian populations and often occurs in younger individuals, it can also present in older patients, where atypical features might increase the risk of misdiagnosis [4,5]. Early recognition is important because uncomplicated cases can frequently be managed conservatively once the correct diagnosis is established [6].

A rare case of uncomplicated cecal diverticulitis was reported in a non-Asian older patient who presented with atypical abdominal pain and significant cardiovascular comorbidities.

Case Presentation

A 57-year-old man presented with acute-onset severe tearing epigastric pain lasting 30 minutes, followed by lower abdominal pain for 6 hours. His past medical history included hypercholesterolemia and a prior percutaneous coronary intervention (PCI) 2 years earlier. He was a non-smoker, physically active, and adhered to a healthy diet.

Correspondence to: Maryam Hafazalla

*Department of Emergency Medicine, Saudi German Hospital, Dubai, United Arab Emirates.

Email: mariammoh635@gmail.com

Full list of author information is available at the end of the article.

Received: 26 January 2026 | Accepted: 11 May 2026

53 Psoas and obturator signs were positive. Although
54 these signs are classically associated with appendicitis,
55 they might also occur in other inflammatory conditions
56 involving the right lower abdomen.

57 Laboratory investigations demonstrated elevated
58 C-reactive protein (70 mg/l) and mild thrombocytopenia
59 (platelets $123 \times 10^9/l$), while white blood cell count,
60 serum lipase, D-dimer, and creatinine were within normal
61 limits. Electrocardiogram and cardiac enzymes showed
62 no evidence of myocardial ischemia.

63 Abdominal ultrasound demonstrated focal thickening
64 of the bowel wall in the right lumbar region with
65 surrounding inflammatory changes and a diverticular
66 out-pouching, raising suspicion for localized colonic
67 inflammation (Figure 1).

68 Subsequent contrast-enhanced computed tomography
69 (CT) of the abdomen and pelvis confirmed a cecal
70 diverticulum with surrounding pericolic fat stranding
71 and localized inflammatory changes involving the cecal
72 wall. No abscess, perforation, or free intraperitoneal
73 air was identified. These findings were consistent with
74 uncomplicated Hinchey stage Ia cecal diverticulitis
75 (Figures 2-4).

76 The patient was admitted to the surgical ward and
77 treated conservatively with bowel rest and intravenous

antibiotics, including ceftriaxone (2 g daily) and
metronidazole (500 mg three times daily). This regimen
provided broad-spectrum coverage against gram-negative
organisms and anaerobic bacteria commonly implicated
in colonic diverticular infections and is widely used in
the treatment of uncomplicated diverticulitis.

Discussion

Cecal diverticulitis is an uncommon cause of acute
abdominal pain in Western populations, representing
approximately 1%-2% of diverticular disease [1]. The
condition is more prevalent in Asian populations, a
geographic variation that might contribute to lower
clinical suspicion and delayed diagnosis in Western and
other settings [5,7].

Cecal diverticulitis has traditionally been described in
younger patients, particularly in Asian cohorts [4,5].
Reports in older patients remain limited in the literature
and might present atypical clinical features, increasing
the likelihood of diagnostic uncertainty [4,8].

Pain localization can further complicate diagnosis. Typical
cecal diverticulitis presents with right lower quadrant
pain that closely resembles acute appendicitis [2,3]. In
the present patient, the initial presentation consisted of
severe epigastric pain followed by lower abdominal pain,

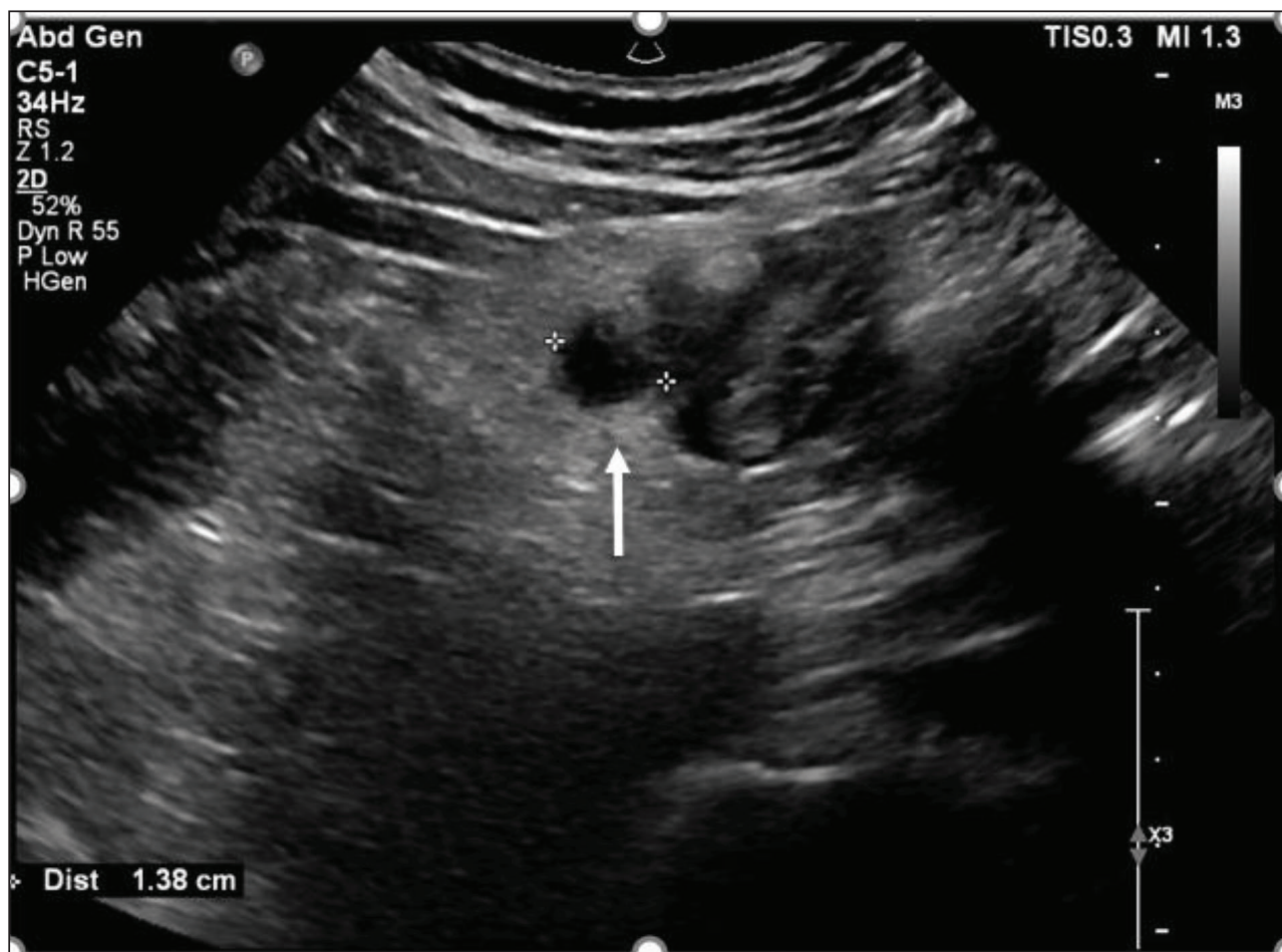


Figure 1. Abdominal ultrasound demonstrating focal thickening of the bowel wall in the right lumbar region measuring up to 10 mm, with surrounding inflammatory fat changes and a diverticular out-pouching (arrow), consistent with localized inflammatory changes.

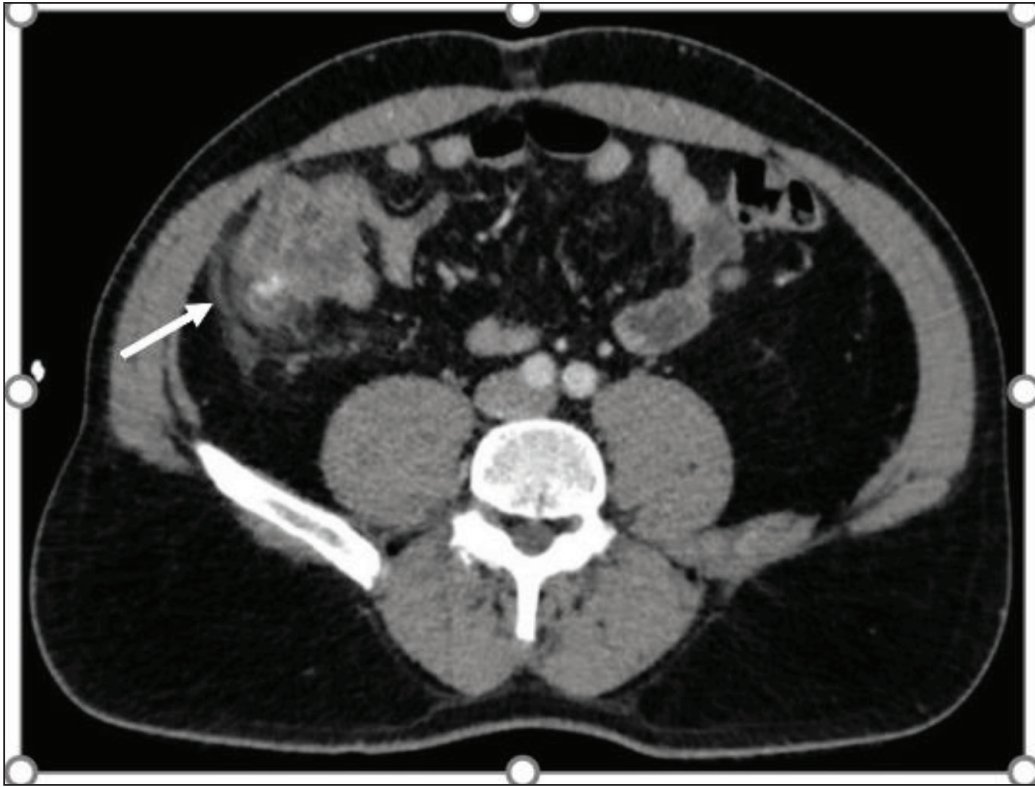


Figure 2. Axial view showing focal mural thickening of the cecum, predominantly involving its posterior aspect, with a diverticular out-pouching and surrounding pericolic fat stranding (arrow), consistent with localized inflammation.

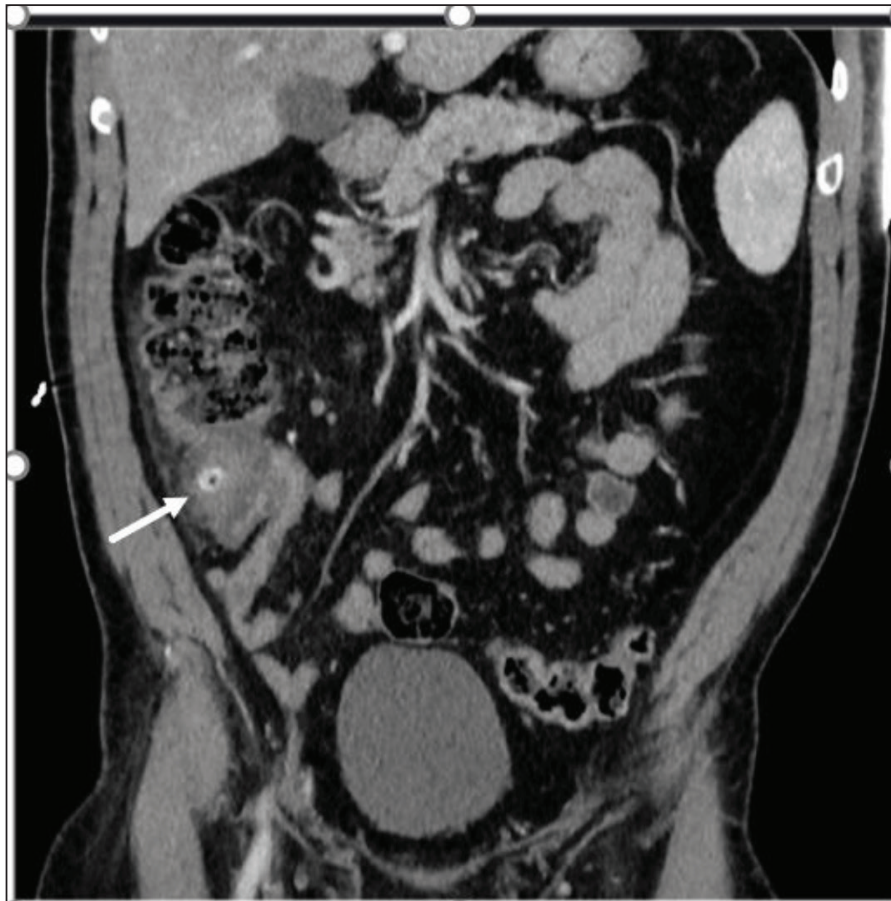

Figure 3. Coronal view demonstrating mild reactive mural thickening at the base of the appendix (arrow) adjacent to the inflamed cecum.

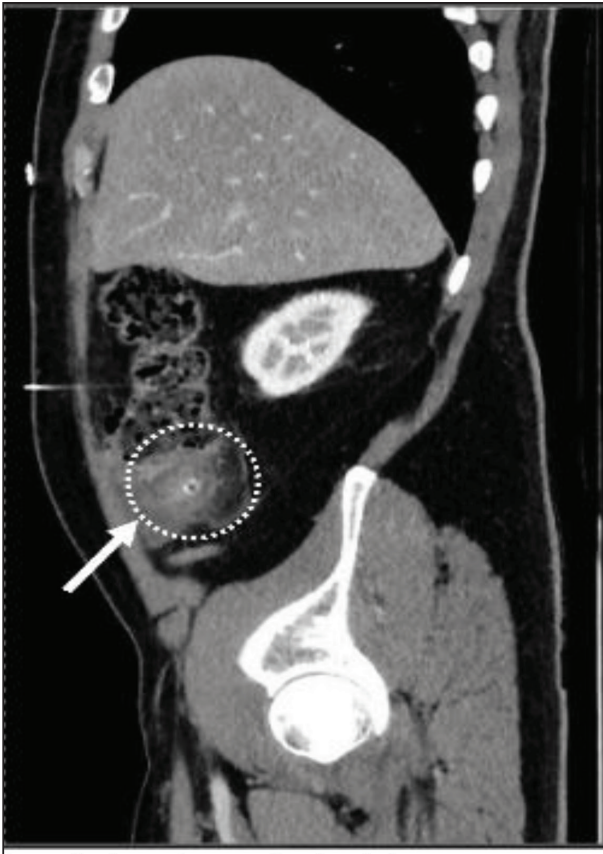

Figure 4. Sagittal view confirming inflammatory changes confined to the cecum without evidence of perforation, abscess, or free intraperitoneal air.

This case contributes to the limited literature describing cecal diverticulitis in older patients and highlights the importance of considering this diagnosis even when patient age, pain location, or comorbidities are atypical.

Following recovery from acute diverticulitis, colonoscopic evaluation is recommended to exclude underlying malignancy or other colonic pathology, particularly in older patients or those with atypical presentations [6].

Conclusion

Cecal diverticulitis might present atypically and mimic other causes of acute abdomen. Early cross-sectional imaging is crucial for accurate diagnosis, and conservative antibiotic therapy is effective in uncomplicated cases.

List of Abbreviations

CT	Computed tomography	144
CRP	C-reactive protein	145
ECG	Electrocardiogram	146
PCI	Percutaneous coronary intervention	147

Conflict of interest

The authors declare that there is no conflict of interest regarding the publication of this article.

Funding

None.

Consent for publication

Written informed consent was obtained from the patient for publication of this case report and the accompanying images.

Ethical approval

Ethical approval is not required at our institution to publish an anonymous case report.

Author details

- Maryam Hafazalla¹, Thomas Coryndon¹, Heba Doudi²
1. Department of Emergency Medicine, Saudi German Hospital, Dubai, United Arab Emirates
 2. Department of Surgery, Saudi German Hospital, Dubai, United Arab Emirates

References

1. Yuksel A, Civil O, Colakoglu MK, Sumer F, Eruyar AT. Solitary cecal diverticulitis, a rare cause of right lower quadrant pain: four cases. *North Clin Istanbul*. 2018. <https://doi.org/10.14744/nci.2017.60565>
2. Nemeth K, Vaughan S. Cecal diverticulitis: a diagnostic conundrum. *Western J Emerg Med*. 2015. <https://doi.org/10.5811/westjem.2015.1.25119>
3. Kroening HL, Rai S. Caecal diverticulitis, an uncommon mimic of appendicitis. *BMJ Case Rep*. 2013. <https://doi.org/10.1136/bcr-2012-007820>
4. Kanyadan P, Lopez Ortiz C, Mangal RK, Stead TS, Ganti L. Cecal diverticulitis in a geriatric patient. *Cureus*. 2022. <https://doi.org/10.7759/cureus.28231>
5. Kyziridis DS, Parpoudi SN, Antoniou ND, et al. Cecal diverticulitis is a challenging diagnosis: a report of 3 cases. *Am J Case Rep*. 2015.

102 which broadened the differential diagnosis. Atypical
103 presentations of cecal diverticulitis have been reported
104 in the literature but remain relatively uncommon, which
105 might delay recognition of the condition [7,9]

106 A history of hypercholesterolemia and prior PCI raised
107 concern for potential vascular or cardiac etiologies
108 during the initial evaluation. As laboratory findings are
109 often nonspecific in this context, imaging played a key
110 role in establishing the diagnosis.

111 Imaging plays a central role in diagnosing cecal
112 diverticulitis. Although abdominal ultrasound may
113 demonstrate bowel wall thickening or localized
114 inflammatory changes, contrast-enhanced CT remains
115 the gold standard for diagnosis, disease staging, and
116 exclusion of complications [6,8]. In our case, CT imaging
117 demonstrated a cecal diverticulum with surrounding
118 pericolic fat stranding consistent with uncomplicated
119 Hinchey stage Ia diverticulitis, without evidence of
120 perforation or abscess formation.

121 Management strategies depend on disease severity.
122 Conservative treatment with bowel rest, intravenous
123 fluids, and antibiotics is recommended for uncomplicated
124 cecal diverticulitis and has demonstrated high rates of
125 successful outcomes [6,8].

126 Surgical intervention is typically reserved for complicated
127 cases, including perforation, abscess formation, or failure
128 of conservative therapy [10].

- 183 6. Tsetse C, Chaudhry SR, Jabi F, et al. Perforated cecal
184 diverticulitis with CT diagnosis and medical management.
185 Radiol Case Rep. 2018. [https://doi.org/10.1016/j.](https://doi.org/10.1016/j.radcr.2018.08.030)
186 [radcr.2018.08.030](https://doi.org/10.1016/j.radcr.2018.08.030)
- 187 7. Blázquez Ávila V, Borrego Rivas S, Jiménez Palacios M, et
188 al. Right-sided diverticulitis. Rev Esp Enferm Dig. 2025.
189 <https://doi.org/10.17235/reed.2024.10418/2024>
- 190 8. Ramos-Cruz I, Sanjuan-Sánchez C, Castillo S, Leyva-
191 Bohórquez P, Cruz-Lucas CF. Acute purulent diverticulitis
192 in the cecum: case report. Cir Cir. 2023. [https://doi.](https://doi.org/10.24875/CIRUE.M21000681)
193 [org/10.24875/CIRUE.M21000681](https://doi.org/10.24875/CIRUE.M21000681)
9. Malek L, Sultan A, Abbas M, Al-Awadhi N. Perforated 194
caecal diverticulitis mimicking acute appendicitis: a case 195
report. Cases J. 2009. [https://doi.org/10.4076/1757-](https://doi.org/10.4076/1757-1626-2-7901) 196
[1626-2-7901](https://doi.org/10.4076/1757-1626-2-7901) 197
10. Shimizu A, Yoshimitsu M, Yano T, et al. Single-incision 198
laparoscopic ileocelectomy for solitary cecal diverticulitis 199
with calcified fecalith. J Surgical Case Rep. 2022. [https://](https://doi.org/10.1093/jscr/rjac323) 200
doi.org/10.1093/jscr/rjac323 201